

Keratic precipitates (KP) in juvenile idiopathic arthritis (JIA)

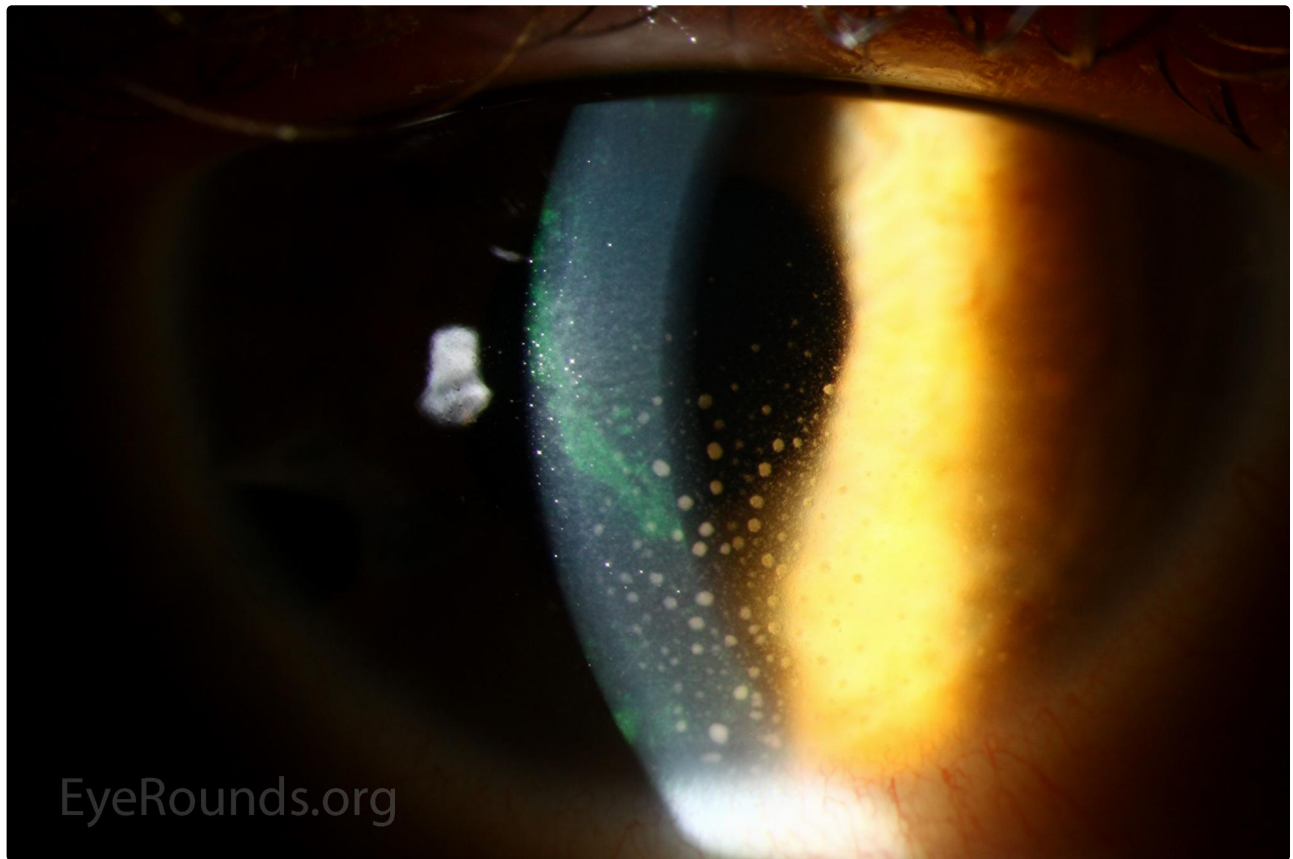
Category(ies): Cornea, Uveitis

Contributor: [Jesse Vislisel, MD](#)

Photographer: Stefani Karakas, CRA



Keratic precipitates (KP) are inflammatory cellular deposits on the corneal endothelium, often seen in the setting of intraocular inflammation. The KP in this photograph were seen in a patient with reactivation of juvenile idiopathic arthritis-associated anterior uveitis.



[Enlarge](#)

[Download](#)

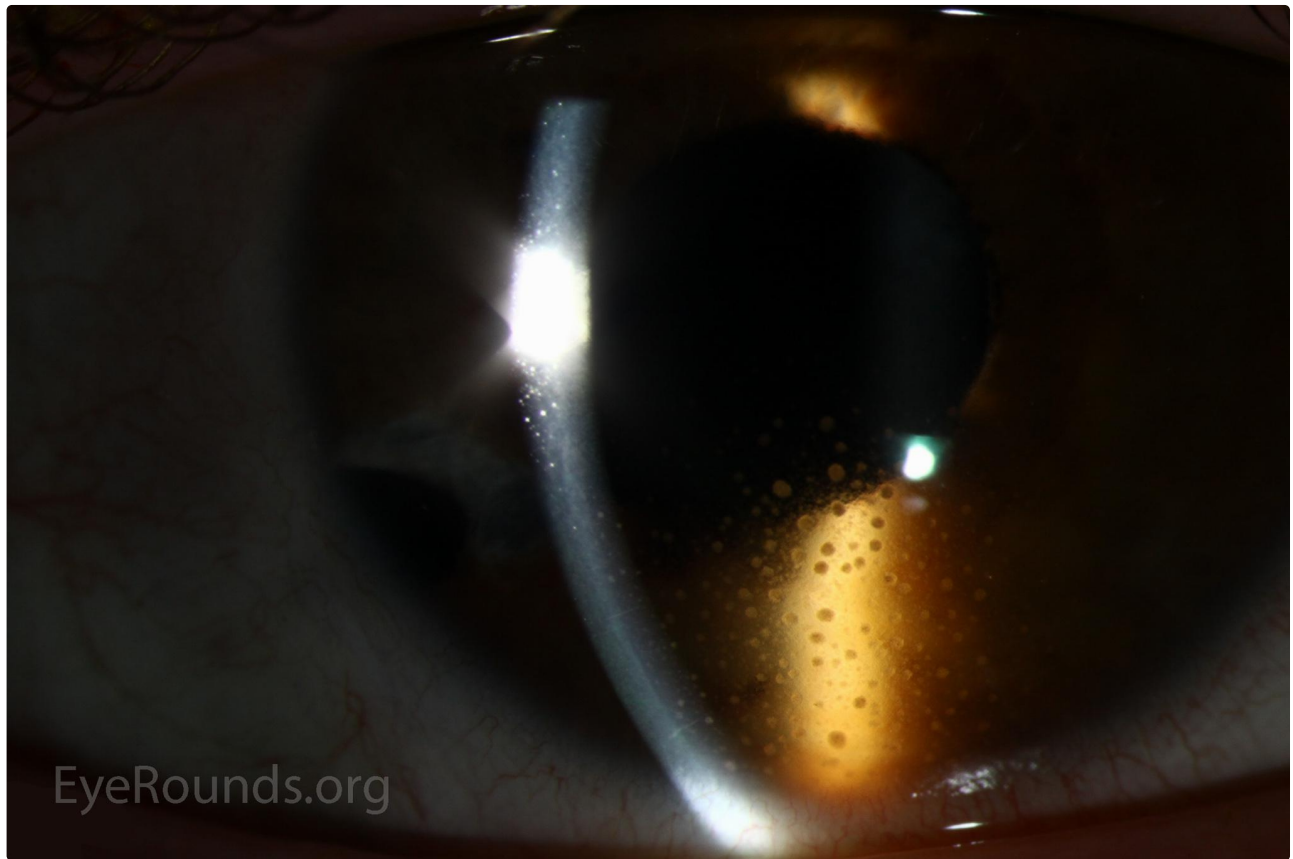
[Enlarge](#)[Download](#)

Image Permissions:



Ophthalmic Atlas Images by [EyeRounds.org](#), [The University of Iowa](#) are licensed under a [Creative Commons Attribution-NonCommercial-NoDerivs 3.0 Unported License](#).

Address

University of Iowa
Roy J. and Lucille A. Carver College
of Medicine
Department of Ophthalmology and
Visual Sciences
200 Hawkins Drive
Iowa City, IA 52242

Legal

Copyright © 2019 The University of
Iowa. All Rights Reserved
Report an issue with this page
Web Privacy Policy |
Nondiscrimination Statement

Related Links

Cataract Surgery for Greenhorns
EyeTransillumination
Gonioscopy.org
Iowa Glaucoma Curriculum
Iowa Wet Lab
Patient Information
Stone Rounds

EyeRounds Social Media

Follow



Receive notification of new cases,
sign up here

